


PATIENT

Sidney Robidart

SPECIES

Feline

BREED

DSH

SEX

Female Spayed

AGE

11 years

WEIGHT

8.1lbs

INTERPRETED BY

 Maggie Machen Lamy,
 DVM DACVIM
 (Cardiology)

IMAGING PERFORMED BY

Amanda Crook, SDEP

HOSPITAL NAME

 Rivers Edge Pet
 Medical Center

REFERRING VET

Dr. Hayes

INVOICE

20709

DATE

8/24/21

PRESENTING CLINICAL SIGNS

History: Not eating canned food. Owner thought she was losing weight. Had actually gained 1#. Small bleeding mass near 409 tooth. Heart skipping beats.

-Blood pressure: HR went from 37 bpm to 180 bpm. Concerned about anesthetic safety to be able to biopsy the oral mass. Doppler on RR leg size 2 cuff - 90, 92, 100, 94, 102, 90mmHg.

ELECTROCARDIOGRAPHIC FINDINGS

A six lead ECG is available at 25mm/s; 10mm/mV. The average heart rate is 160bpm (range is 150-188bpm) with a largely regular rhythm. The rhythm is sinus in origin, with a p for every QRS complex and vice versa although baseline artifact impedes identification throughout. The P wave morphology is positive with a normal dimension. Normal PR. The QRS morphology is low voltage. Isolated VPCs throughout; monomorphic, singles only.

No supraventricular premature beats, pauses or other dysrhythmias observed.

ECG diagnosis: Normal sinus tachycardia with isolated VPCs.

ECHOCARDIOGRAM FINDINGS

2D, m-mode, color flow and doppler imaging is available. The left ventricular walls are normal in diameter. There is a diffusely hyperechoic endocardium consistent with fibrosis. False tendon. The endocardium also appears mildly remodeled. The left atrium is normal in size. No mitral regurgitation; MV appears normal. The right atrium is normal in size. The right ventricle appears normal (subjective). Mild TR. Normal TR velocity. Blood flow through the RVOT is normal in velocity. No obvious PI or AI. No obvious LVOTO/SAM on 2D imaging. No obvious cardiac tumors identified. No effusions.

CARDIAC CHART

FELINE CARDIAC PARAMETERS	BODY WEIGHT (kg)	HR (BPM)	IVSd (cm) <small>(Moise, Pipers)</small>	LVIDd (cm) <small>(Moise, Pipers)</small>	LVWd (cm) <small>(Moise, Pipers)</small>	FS (%)	EF (%)
NORMAL PARAMETER	-----	150-240	0.35-0.55	<2 (mean 1.5)	3.5-0.55	35-67	80-100
PATIENT	3.7	180	0.49	1.22	0.44	50	94
FELINE CARDIAC PARAMETERS	LA/AO <small>(Boon)</small>	LA/AO HEART BASE <small>(Swe) (Abbott)</small>	LA 2D short axis Base view (cm) <small>(Abbott)</small>		LVOT VEL (m/s)	RVOT VEL (m/s)	E max (m/s)
NORMAL	<1.5	<1.3	<1.2		<1.6	<1.3	<0.9
PATIENT	1.4	1.2	1.2		1.1	1.0	NM

**Note: All measurements based upon multi-modal images and methods. An average value is reported.*

Adapted from June Boon, Veterinary Echocardiography, 1998
 Abbott J & MacLean H JVIM 2006;20: 111-119, Moise et al. Am J Vet Res 47:1476, 1986. Pipers et al. Am J Vet Res 40:882, 1979.



PATIENT

Sidney Robidart

SPECIES

Feline

BREED

DSH

SEX

Female Spayed

AGE

11 years

WEIGHT

8.1lbs

INTERPRETED BY

Maggie Machen Lamy,
DVM DACVIM
(Cardiology)

IMAGING PERFORMED BY

Amanda Crook, SDEP

HOSPITAL NAME

Rivers Edge Pet
Medical Center

REFERRING VET

Dr. Hayes

INVOICE

20709

DATE

8/24/21

INTERPRETATION OF THE FINDINGS & FURTHER RECOMMENDATIONS

Overtly normal geriatric cardiac structure and function with normal LV wall measurements and diffuse remodeling/fibrosis. This degree of abnormality is suspected to be a normal age-related finding, however serial monitoring is recommended to screen for progressive changes. The LA is normal at this time however, indicating a low risk for clinical complications at this time.

The only arrhythmia identified on the ECG are isolated VPCs. No obvious cardiac cause of VPCs is identified in this study, although fibrotic tissue alone can theoretically lead to their development. Extra-cardiac factors such as stress, pain, inflammation, systemic disease, etc. should be considered and ruled out. No therapy is warranted for what is seen here; however, monitoring for sustained tachyarrhythmias is advised. Monitor for any signs of progressive arrhythmia, including significant lethargy or collapse/syncope. Sudden death is unfortunately always a possibility in animals with arrhythmias, regardless of anti-arrhythmic therapy.

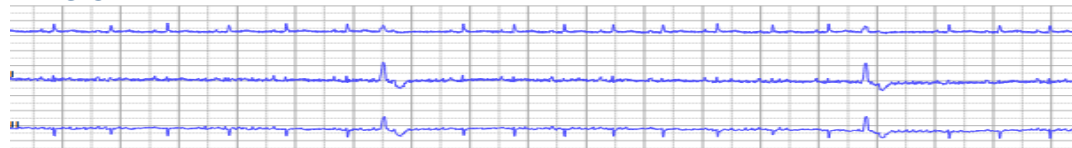The dramatic heart rate variation noted in the history was not appreciated on an extended ECG tracing. If this was thought to be a real finding that is persistently ausculted, further in-hospital monitoring may be useful in this case.

Based upon what is seen here, anesthetic risk is considered moderate with ventricular arrhythmias, and judicious IV fluid rates are advised to avoid fluid overload. Additionally, drugs that stimulate heart rate should be avoided unless clinically necessary (glycopyrrolate, atropine). Avoid ketamine, telazol, alpha 2 agonists. A reasonable protocol includes opioid/benzodiazepine premedication, propofol induction, isoflurane maintenance. Monitor ECG intra and post-operatively, with careful intervention if ventricular arrhythmias are sustained (i.e., sustained VT) and lead to hemodynamic compromise.

Monitor for any development of clinical signs at home, including labored breathing, cough or signs of a blood clot (paralysis, neurologic change).

No cardiac medications are clearly indicated. A recheck echocardiogram and ECG are recommended in 6-12 months to screen for progressive LV changes.

IMAGES





PATIENT

Sidney Robidart

SPECIES

Feline

BREED

DSH

SEX

Female Spayed

AGE

11 years

WEIGHT

8.1lbs

INTERPRETED BY

Maggie Machen Lamy,
DVM DACVIM
(Cardiology)

IMAGING PERFORMED BY

Amanda Crook, SDEP

HOSPITAL NAME

Rivers Edge Pet
Medical Center

REFERRING VET

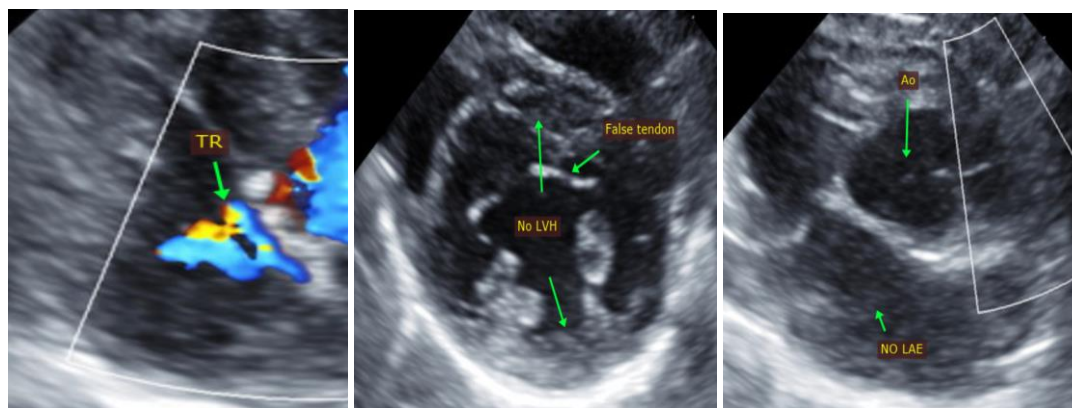
Dr. Hayes

INVOICE

20709

DATE

8/24/21



The information and recommendations provided are based on the images presented by the referring veterinarian. No evaluation can be communicated regarding pathology that was not visible in the image/video clips provided.

Thank you for this referral. This report was generated using transcription software, and minor dictation errors may be present. If the clinical or image interpretation does not parallel your findings or if I can be of any further assistance, please contact me.

Maggie Machen Lamy, DVM
Diplomate of the American College of Veterinary Internal Medicine (Cardiology)
info@sonopath.com